

Etiology and Conservative Treatment of Carpal Tunnel Syndrome

Alan L. Miller, N.D. and Timothy C. Birdsall, N.D.

Abstract

Carpal tunnel syndrome (CTS) is a neuropathy caused by entrapment and compression of the median nerve as it passes through the carpal tunnel in the wrist, leading to a decrease in nerve transmission to and from the hand. Symptoms include pain, numbness, tingling, aching, and loss of motor and sensory function in the first three digits of the hand. These symptoms are typically worse at night and can awaken the individual. CTS is more common in women than men, and is a common occurrence in occupations involving repetitive motions of the upper extremity. A vitamin B6 deficiency has been found in many patients with CTS, and treatment with B6 or its bioactive form, pyridoxal 5' phosphate, is helpful in the majority of cases. Addressing the individual's occupational biomechanical and/or ergonomic factors, in addition to manual manipulation and the therapeutic use of anti-inflammatory substances such as bromelain can be of significant benefit and may decrease the need for carpal tunnel release surgery. (*Alt Med Rev* 1997;2(1):26-35)

Introduction

Carpal tunnel syndrome (CTS) has been defined as an entrapment neuropathy of the median nerve as it passes through the space created by the carpal bones of the wrist and the transverse carpal ligament (flexor retinaculum), often resulting in a loss of sensory and motor nerve function. Any process which can occupy space may cause compression and malfunction of the nerve, including edema, fibrosis, tuberculosis, acromegaly, rheumatoid and osteoarthritis, sarcoidosis, amyloidosis, tumors, recent or poorly healed fractures, and multiple myeloma. Endocrinological problems such as diabetes mellitus and hypo- and hyperthyroidism may also cause CTS symptoms. However, idiopathic localized tenosynovitis is considered to be the most common cause, especially in middle-aged females. Of increasing concern in recent years is occupational carpal tunnel syndrome (OCTS), usually related to repetitive movements of the upper extremity, especially those involving flexion or extension of the wrist. (See Figure 1)

Diagnosis

A complete history of the patient's symptomatology, work habits, and other potential etiological factors should point the practitioner to the etiology. However, due to the numerous potential causes of CTS it may be necessary to rule out the above-mentioned compressive, inflammatory, and endocrinological factors. Typically, the patient presents with pain and paresthesias in the distribution of the median nerve, either unilaterally or bilaterally. Often, the

patient's chief complaint is awakening at night with paresthasias in the hand. They may also complain of "clumsiness" during activities requiring fine motor skills, such as buttoning, writing or sewing. CTS can be differentiated from thoracic outlet syndrome, in which the entire hand, or perhaps the ulnar portion of the hand, is more likely to be involved. In lesions involving the nerve root, the patient rarely is awakened at night with paresthasias, and use of the hand does not bring on symptoms.

Neurological tests such as Tinel's (tapping the palmar surface of the wrist in hyperextension causing tingling into the median nerve distribution of the hand) and Phalen's (sustained flexion of the wrist for 60 seconds or less causing CTS symptoms) can be helpful in diagnosing CTS. Electromyographic (EMG) studies may also be utilized to differentially diagnose CTS, with decreased nerve conduction velocities and increased distal motor latencies in the median nerve frequently seen.

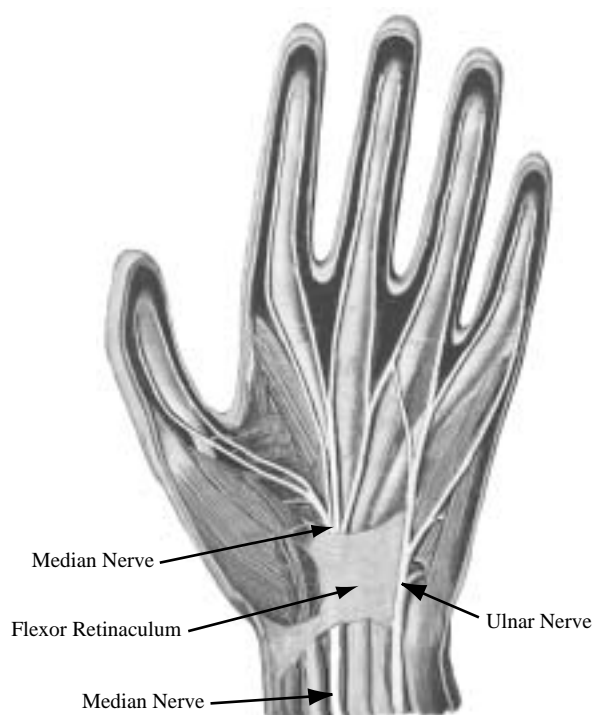
Conservative allopathic treatment consists of splinting the wrist, non-steroidal anti-inflammatory drugs, and steroid injections. Surgical decompression of the carpal tunnel is often effective in advanced cases.

CTS is more common in women, especially those who are pregnant or taking oral contraceptives, conditions which have been associated with an increased need for vitamin B6.¹ In patients with CTS, vitamin B6 deficiency is often found,²⁻⁷ and many clinical and double-blind studies have demonstrated that vitamin B6 supplementation can alleviate the symptoms of CTS,^{1,3-13} even in those patients without laboratory evidence of a vitamin B6 deficiency.¹² A few studies have shown no clinical benefit from B6 supplementation.¹⁴⁻¹⁶

A study of 994 patients diagnosed with CTS revealed that 395 (38%) associated their symptoms to their job. In patients treated allopathically, only 14.3% had satisfactory alleviation of symptoms using combinations of splinting, NSAIDs, job/activity change, and steroid injections. Carpal tunnel release surgery occurred in 20%. In 494 patients subsequently treated with B6 (pyridoxine 100 mg. bid) alone or in combination with splints and/or a job change, 68% had complete or satisfactory alleviation of symptoms. The authors suggest that those who suffer from occupationally-induced CTS have a predisposition to carpal tunnel syndrome which is aggravated by their occupational activities. It is interesting to note that 42.5% of these patients had undergone hysterectomy or oophorectomy, which may be a factor.⁹

FIGURE 1. Nerve Distribution of the Hand

Note - The median nerve passes beneath the flexor retinaculum, but the ulnar nerve does not.



phy of the thenar muscles a 12-week trial of B6 (100-200 mg/day) is warranted. If the CTS has progressed to thenar atrophy, the patient should still be put on B6 long-term; however, a surgical consult may be necessary.^{1,4}

Pyridoxal 5' Phosphate, The Bioactive B6

Vitamin B6, a nutrient essential in amino acid metabolism, neurotransmitter synthesis and glycogen breakdown, is widespread in nature, but is found only in small amounts. While pyridoxine HCl has been the standard B6 supplement, pyridoxal 5' phosphate (PLP) is the active, coenzyme form of B6 and is the only form which can be used by the enzymes involved in biochemical processes associated with nitrogen and protein metabolism and heme synthesis.¹⁷ PLP is the coenzyme for aspartate aminotransferase (AST, also known as SGOT), the enzyme which catalyzes transamination of aspartate to glutamate, and alanine aminotransferase (ALT, also known as SGPT). Assays for these enzymes, which are thought to leak from hepatocytes during liver injury, are among the most frequently performed laboratory tests, and are used to assess hepatocellular damage.¹⁸ If PLP status is compromised, however, AST and ALT levels may be abnormally low. In addition, PLP is required in enzymatic processes responsible for the deamination and transamination of amino acids, deamination of hydroxy-amino acids and cysteine, conversion of tryptophan to niacin, synthesis of picolinic acid, and metabolism of most fatty acids.

Although the enzymes necessary to transform the various dietary forms of B6 into active PLP have been found in the brain, erythrocytes, spleen and kidneys,^{19,20} the majority of the enzymatic conversion to PLP occurs in the liver.²¹ An abundance of pyridoxine phosphate oxidase in the liver, and

a unique transport mechanism also point to the liver as the main source of PLP. Therefore, patients with impaired liver function are at greatest risk for functional vitamin B6 deficiency, unless supplemented with the active form.

The Effect of Liver Function on Pyridoxal 5' Phosphate Formation

Several studies using subjects with compromised livers have supported the theory that the liver is the primary site of PLP formation. Up to 90% of those with severe cirrhosis suffer from B6 deficiency.¹⁸ Acute episodes of excessive alcohol intake¹⁷ and chronic alcohol abuse have been shown to depress plasma levels of PLP,²² presumably by altering hepatic phosphorylation of pyridoxal. One study compared the effect of administration of pyridoxine HCl versus PLP in three alcoholic subjects, two of which suffered from hyperferremia and bone-marrow sideroblastic changes. Serum iron decreased significantly and sideroblastic abnormalities reverted to normal when PLP was administered, but not with pyridoxine HCl.²³ In another investigation using eight vitamin B6-deficient cirrhotic patients, pyridoxine HCl (50 mg twice a day) increased plasma PLP levels in only four of the subjects on average from 2.4 to 18.5 ng/ml. PLP (50 mg twice daily), on the other hand, was effective in all eight subjects, increasing plasma PLP levels on average from 3.3 to 27.0 ng/ml.¹⁸ Labadarios et al found that pyridoxine HCl increased plasma PLP in only 33% of those with liver disease, while all patients responded to PLP supplementation.²⁴

Riboflavin and CTS

Folkers, et al found that a deficiency of riboflavin (vitamin B2) may affect the utilization of B6. He found "many patients with

CTS” who demonstrated deficiencies of B2 and B6. CTS patients were tested for riboflavin deficiency by measuring the activity of the riboflavin-dependent enzyme erythrocyte glutathione reductase (EGR) and B6 deficiency by testing the activity of erythrocyte glutamic-oxaloacetic transaminase (EGOT). In a single-case study, after five months’ treatment with 50 mg riboflavin, the patient subjectively improved to the point of having only mild, intermittent CTS symptoms. The patient’s objective evaluation (pinch strength) also improved significantly ($p < 0.001$). EGR activity increased during this time period, indicative of a positive outcome of treatment for the riboflavin deficiency. The addition of 500 mg pyridoxine HCl for three months increased the activity of EGOT, as well as the activity of EGR. The patient was symptom-free after this combined therapy.⁶ The positive response in this patient may be due to the dependence on riboflavin for the bioconversion of pyridoxine to the phosphorylated, active form of vitamin B6, pyridoxal-5’ phosphate; thus a riboflavin deficiency can cause a functional PLP deficiency.^{6,25,26} This dependence on riboflavin for B6 conversion provides an argument for supplementing riboflavin when using pyridoxine in CTS. Moreover, it provides a rationale for the use of PLP in carpal tunnel syndrome, as PLP is the active form and does not need to be converted.

Pyridoxine “Toxicity”

Supplementation with high doses of pyridoxine can cause a peripheral neuropathy, possibly by overloading the liver’s capacity to phosphorylate pyridoxine to PLP. Thus, pyridoxine may compete with PLP for binding sites, effectively shutting off PLP from exerting its effects and causing a relative PLP deficiency.²⁷ There have been no published

reports of peripheral neuropathy with supplementation of PLP.

Bromelain: Effective Anti-Inflammatory

Bromelain, the enzyme fraction obtained from the pineapple plant, has also been used clinically with success in the treatment of CTS. Initially introduced as a therapeutic agent in 1957, bromelain is usually derived from the stem of the plant, and is a mixture of several proteases and small amounts of non-proteolytic enzymes. Physiologic actions of bromelain include: anti-inflammatory action, smooth muscle relaxation, inhibition of blood platelet aggregation, improved wound healing, and when taken with meals, enhanced digestion.²⁸⁻³⁸

Several mechanisms may account for bromelain’s widely utilized anti-inflammatory effects: 1) enhanced proteolytic activity at sites of inflammation; 2) fibrinolysis activity via the plasminogen-plasmin system; 3) depletion of kininogen; and 4) inhibition of biosynthesis of pro-inflammatory prostaglandins and induction of PGE-1 accumulation.^{29,31,32,38} While bromelain has been demonstrated to be absorbed intact (up to 40% of ingested amount), the proteolytic actions are inhibited by serum factors,^{31,32} suggesting that the first mechanism has only limited effect under normal circumstances. The latter three mechanisms are closely interrelated, since after tissue injury, the kinin, complement, fibrinolytic and clotting systems are all activated.

Fibrin’s role in promotion of the inflammatory response is to form a matrix that walls off the area of inflammation resulting in blockage of blood vessels and inadequate tissue drainage, while the kinin system cascade results in the production of kinins (e.g., bradykinin and kallidin) which increase

vascular permeability causing edema as well as evoking pain. The potent ability of bromelain to deplete plasma kininogen (the kinin precursor) and activate fibrinolysis by stimulating plasmin production via plasminogen activation, results in depolymerization of fibrin, thereby preventing fibrin clogged venous stasis and edema.^{31,32} Perhaps more importantly, plasmin has been shown to block the mobilization of arachidonic acid by phospholipases, reducing the production of pro-inflammatory prostaglandins and leukotrienes.³³

The effect of orally administered bromelain on the reduction of edema, bruising, healing time and pain following various surgical procedures has been demonstrated in many clinical studies.^{28-30,34,36,37} Walker et al demonstrated that bromelain administered orally following trauma significantly reduced the development of injury in skeletal muscle.²⁸

Bromelain is also used in treating a wide variety of trauma-related injuries, especially sports-related injury. In a study involving boxers, bromelain cleared all signs of bruising within 4 days in 78% of the boxers, the remainder clearing completely in 8 to 10 days. In comparison, the control group had only 14% clearance after 4 days.³⁶

Bromelain is virtually non-toxic (no LD₅₀ exists up to 10 g/kg), and long-term use appears to be well tolerated.³⁰ Although no significant side effects have been noted, allergic reactions may occur in sensitive individuals, and use should cease immediately if sensitivity manifests (urticaria or skin rash has been noted). Unless bromelain is being used as a digestive aid, administration is usually recommended on an empty stomach (at least one hour prior to, and no less than two hours after eating). In carpal tunnel syndrome, 1000 mg of a bromelain with at least 3000 m.c.u./ gram potency is typically

dosed three times a day, between meals. Several practitioners report that the combination of bromelain with pyridoxal 5' phosphate in the treatment of CTS yields results superior to the use of pyridoxine HCl alone (see accompanying practitioner interviews).

Manipulative Treatment of CTS

Manipulation of the carpal bones has been shown to be helpful in the treatment of CTS. In a study of 20 abnormal wrists, all were found to be at least moderately restricted in their range of motion, compared to mild or no restriction in control wrists. Doctor manipulation and patient-initiated stretching resulted in an increased range of motion of the carpal bones into the normal range, followed by improvement in nerve conduction studies within 1 to 3 months.³⁹

Treatment of four patients with myofascial release manipulation and self-stretching resulted in improved distal latencies and motor neuron amplitudes, along with an MRI-documented increase in AP and transverse dimensions of the carpal tunnel.⁴⁰

Wong and colleagues, in a study of 35 female office workers diagnosed with CTS due to a repetitive stress injury, found that these individuals had pain and tenderness to palpation at the spinous processes of C5-T1 and at the medial angle of the scapula. Low level laser (100 mW) was used to treat the pain at the spinous processes, with subsequent resolution of pain and paresthesias in the arms and hands, and a reduction in pain at the spinous processes. It was theorized that because of poor posture, with the head and neck forward and shoulders rounded, these workers develop a cervical spine radicular dysfunction resulting in CTS symptomatology.⁴¹

Conclusion

The symptoms and life impact of carpal tunnel syndrome can range from a bothersome nuisance to a chronic, disabling disease process. Researchers have found a direct correlation between CTS and a deficiency in the bioactive form of vitamin B6, pyridoxal 5' phosphate (PLP) and have found that treatment with 100-200 mg/day of pyridoxine for at least 12 weeks is highly beneficial in reducing the symptomatology and B6 deficiency associated with CTS.

Carpal tunnel syndrome is very prevalent in workers whose occupation requires them to perform forceful, repetitive motions with the upper extremities. Some researchers suggest that these individuals have a biochemical predisposition to developing CTS which is uncovered by their repetitive physical stress. Combinations of vitamin B6, splinting and job change have been shown to be significantly effective in treating CTS, and more effective than B6 supplementation alone. The addition of the anti-inflammatory bromelain and manual manipulation of the wrist can be of further benefit, along with postural education, in the conservative treatment of CTS.

References

1. Ellis JM. Treatment of carpal tunnel syndrome with vitamin B6. *South Med J* 1987;80:882-884.
2. Fuhr JE, Farrow A, Nelson HS Jr. Vitamin B6 levels in patients with carpal tunnel syndrome. *Arch Surg* 1989;124:1329-1330.
3. Ellis J, Folkers K, Watabe T, et al. Clinical results of a cross-over treatment with pyridoxine and placebo of the carpal tunnel syndrome. *Am J Clin Nutr* 1979;32:2040-2046.
4. Ellis J, Folkers K, Levy M, et al. Therapy with vitamin B6 with and without surgery for treatment of patients having the carpal tunnel syndrome. *Res Comm Chem Pathol Pharmacol* 1981;33:331-343.
5. Ellis JM, Folkers K, Levy M, et al. Response of vitamin B-6 deficiency and the carpal tunnel syndrome to pyridoxine. *Proc Natl Acad Sci* 1982;79:7494-7498.
6. Folkers K, Wolaniuk A, Vadhanavikit S. Enzymology of the response of the carpal tunnel syndrome to riboflavin and to combined riboflavin and pyridoxine. *Proc Natl Acad Sci* 1984;81:7076-7078.
7. Ellis J, Folkers K, Minadeo M, et al. A deficiency of vitamin B6 is a plausible molecular basis of the retinopathy of patients with diabetes mellitus. *Biochem Biophys Res Commun* 1991;179:615-619.
8. Ellis JM, Kishi T, Azuma J, Folkers K. Vitamin B6 deficiency in patients with a clinical syndrome including the carpal tunnel defect. Biochemical and clinical response to therapy with pyridoxine. *Res Comm Chem Pathol Pharmacol* 1976;13:743-757.
9. Kasdan ML, Janes C. Carpal tunnel syndrome and vitamin B6. *Plastic Reconstruct Surg* 1987;79:456-459.
10. Wolaniuk A, Vadhanavikit S, Folkers K. Electromyographic data differentiate patients with the carpal tunnel syndrome when double blindly treated with pyridoxine and placebo. *Res Comm Chem Pathol Pharmacol* 1983;41:501-511.
11. Amadio PC. Pyridoxine as an adjunct in the treatment of carpal tunnel syndrome. *J Hand Surg* 1985;10:237-241.
12. Laso Guzman FJ, Gonzalez-Buitrago JM, de Arriba F, et al. Carpal tunnel syndrome and vitamin B6. *Klin Wochenschr* 1989;67:38-41.
13. Bernstein AL, Dinesen JS. Brief communication: Effect of pharmacological doses of vitamin B6 on carpal tunnel syndrome, electroencephalographic results, and pain. *J Am Coll Nutr* 1993;12:73-76.
14. Spooner GR, Desai HB, Angel JF, et al. Using pyridoxine to treat carpal tunnel syndrome. Randomized control trial. *Can Fam Phys* 1993;39:2122-2127.
15. Stransky M, Rubin A, Lava N, Lazaro R. Treatment of carpal tunnel syndrome with vitamin B6: a double-blind study. *South Med J* 1989;82:841-842.
16. Franzblau A, Rock CL, Werner RA, et al. The relationship of vitamin B6 to median nerve function and carpal tunnel syndrome among active industrial workers. *J Occup Environ Med* 1996;38:485-491.

17. Parker TH, Marshall JP, Roberts RK, et al. Effect of acute alcohol ingestion on plasma pyridoxal 5'-phosphate. *Am J Clin Nutr* 1979;32:1246-1252.
18. Rossouw JE, Labadarios D, Davis M, Williams R. Vitamin B6 and aspartate aminotransferase activity in chronic liver disease. *S African Med J* 1978;53:436-438.
19. Anderson BB, Fulford-Jones CE, Child JA, et al. Conversion of vitamin B6 compounds to active forms in the red blood cell. *J Clin Invest* 1971;50: 1901-1909.
20. Lumeng L, Brashear RE, Li T-K. Pyridoxal 5'-phosphate in plasma: source, protein-binding, and cellular transport. *J Lab Clin Med* 1974; 84:334-343.
21. Lumeng L, Lui A, Li TK. Plasma content of B6 vitamers and its relationship to hepatic vitamin B6 metabolism. *J Clin Invest* 1980; 66:688-695.
22. Mitchell D, Wagner C, Stone WJ, et al. Abnormal regulation of plasma pyridoxal 5'-phosphate in patients with liver disease. *Gastroenterology* 1976;71: 1043-1049.
23. Hines JD, Cowan DH. Studies on the pathogenesis of alcohol-induced sideroblastic bone marrow abnormalities. *N Engl J Med* 1970; 283:441-446.
24. Labadarios D, Rossouw JE, McConnell JB, et al. Vitamin B6 deficiency in chronic liver disease- evidence for increased degradation of pyridoxal 5'-phosphate. *Gut* 1977;18:23-27.
25. Lowik MR, van den Berg H, Kistemaker C, et al. Interrelationships between riboflavin and vitamin B6 among elderly people (Dutch Nutritional Surveillance System). *Int J Vitamin Nutr Res* 1994;64:198-203.
26. Kodentsova VM, Iakushina LM, Vrhesiskaia OA, et al. Effects of riboflavin administration on vitamin B6 metabolism. *Vopr Pitan* 1993; 5:32-36.
27. Parry GJ, Bredesen DE. Sensory neuropathy with low-dose pyridoxine. *Neurology* 1985; 35:1466-1468.
28. Walker JA, Cerny FJ, Cotter JR, Burton HW. Attenuation of contraction-induced skeletal muscle injury by bromelain. *Med Sci Sports Exerc* 1992;24:20-25.
29. Felton G. Fibrinolytic and anti-thrombotic action of bromelain may eliminate thrombosis in heart patients. *Med Hypotheses* 1980; 6:1123-1133.
30. Taussig S, Yokoyama M, Chinen A, et al. Bromelain, a proteolytic enzyme and its clinical application. A review. *Hiroshima J Med Sci* 1975;24:185-193.
31. Taussig S. The mechanism of the physiologic action of bromelain. *Med Hypothesis* 1980;6:99-104.
32. Taussig SJ ; Batkin S. Bromelain, the enzyme complex of pineapple (*Ananas comosus*) and its clinical application. An update. *J Ethnopharmacol* 1988;22:191-203.
33. Schafer A, Adelman B. Plasmin inhibition of platelet function and arachidonic acid metabolism. *J Clin Invest* 1985;75:456-461.
34. Tassman G, Zafran J, Zayon G. Evaluation of a plant proteolytic enzyme for the control of inflammation and pain. *J Dent Med* 1964; 19:73-77.
35. Tassman G, Zafran J, Zayon G. A double-blind crossover study of a plant proteolytic enzyme in oral surgery. *J Dent Med* 1965;20:51-54.
36. Howat R, Lewis G. The effect of bromelain therapy on episiotomy wounds—A double-blind clinical trial. *J Ob Gyn Br Commonwealth* 1972;79:951-953.
37. Blonstein J. Control of swelling in boxing injuries. *Practitioner* 1960;203:206.
38. Kelly G. Bromelain: A literature review and discussion of its therapeutic applications. *Alt Med Rev* 1996;1(4):243-257.
39. Sucher BM. Palpatory diagnosis and manipulative management of carpal tunnel syndrome. *J Am Osteopath Assoc* 1994;94:647-663.
40. Sucher BM. Myofascial manipulative release of carpal tunnel syndrome: documentation with magnetic resonance imaging. *J Am Osteopath Assoc* 1993;93:1273-1278.
41. Wong E, Lee G, Zucherman J, Mason DT. Successful management of female office workers with "repetitive stress injury" or "carpal tunnel syndrome" by a new treatment modality—application of low level laser. *Int J Clin Pharmacol Ther* 1995;33:208-211.

Practitioner Interviews on Carpal Tunnel Syndrome

Question - What are your general thoughts regarding the Carpal Tunnel Syndrome (CTS) patient?

Dr. Cox - *“I’ve seen quite a few patients who have not presented with classic CTS symptoms, but rather have identified upper back pain, etc. as their chief complaint, with only a passing reference to arm or hand pain, numbness, weakness or paresthesias. To make a long diagnostic story short, eventually CTS is diagnosed with the aid of an EMG study. So, I now start thinking CTS whenever a patient’s complaints include any of the classic signs and symptoms, even if they are de-emphasized by the patient.”*

Dr. Martinez - *“I think that the main thing is that the more overt the syndrome, the less likely it is that the patient is going to respond favorably, so you focus your differential on the severity of the symptoms. For example, are they awakened by it every night, or is it something that just bothers them when they are using the extremity?”*

That makes it more of a practical application. I see a few groups of patients: the subclinical patients, where they are bothered occasionally, only with activity; others are bothered just by their occupation, that is regularly; and then the truly symptomatic group, with mild to severe disability.”

Dr. Tyler - *“Because of the extensive research connecting vitamin B6 deficiency to CTS, I want to examine the patient’s diet for adequate B6 intake, but more importantly looking for B6 antagonists, such as yellow dye #5, and drugs like hydralazine, dopamine,*

penicillamine, oral contraceptives, and even excessive protein intake. These can all render the patient functionally B6 deficient. A word of caution - megadoses of pyridoxine HCl can be toxic and may even cause nerve damage if taken in massive doses over a long period of time. For this reason, I prefer the activated form of B6, pyridoxal 5' phosphate.”

Question - What are some of the biomechanical issues that you see in these patients?

Dr. Cox - *“In many of these patients it is critical to get them to change their sleeping posture. So often they are sleeping on their stomachs, resulting in significant spinal rotation, especially at the cervical-dorsal junction. A wrist splint is very helpful, since it prevents both hyperflexion and hyperextension of the wrist. Wearing the splint at night will prevent the unconscious hyperflexion which causes so much of the night-waking with paresthesias. I also recommend exercises both to stretch the muscles of the chest (pectoralis major and minor, subclavius) and to strengthen the muscles of the upper back (levator scapulae, rhomboids, upper and lower trapezius). I want them to limit their use of weight machines which build up the pectoral muscles, and rowing machines, which don’t work the shoulders far enough posteriorly.”*

Dr. Martinez - *“Resolution of some of the biomechanical factors can really help to take the stress off of the median nerve. When people are sitting, they may do toe pointing, that is, sitting with their feet pulled back and their toes pointed. This contracts gastroc/soleus, which pitches the head forward and can be a perpetuating factor in CTS. If they have to hold their shoulders up, because the chair isn’t high enough when working at a table or countertop, then wrist rests are helpful. If there are*

repetitive actions involved in their occupation, then it is important for them to figure out how to vary the activity so that they don't chronically use just one set of muscles. I also find it important to have patients do stretching exercises aimed at the pectoral group and the scalenes."

Dr. Tyler - "From a therapeutic standpoint you may wish to look for a subluxation of the spine at C-6 through T-1 levels affecting part of the brachial plexus and thus contributing to its hypersensitivity. Using wrist splints is helpful in trying to avoid excessive flexion and extension movements of the joint. Even after recovery, I recommend that the splint be worn if the patient is going to engage in activity which could reactivate the condition, e.g., operating a computer or typing for long periods of time. Gentle lateral bending of the wrist is sometimes helpful in retaining the patency of the carpal tunnel."

Question - Other than dealing with biomechanical issues and exercise, what is your general therapeutic approach to the CTS patient?

Dr. Cox - "I give 2 capsules of a 500 mg, 3000-5000 m.c.u./gram bromelain 3 times a day, always between meals. I also have the patient take 100 mg of pyridoxal 5' phosphate twice daily. My experience in the past has been that using regular pyridoxine hydrochloride alone gave mixed to poor results."

Dr. Tyler - "I have used galvanic iontophoresis of bromelain with some success. Dissolve 6 capsules of pure bromelain in 3 ounces of warm water, and apply the solution to the positive pad and lace it over the area of the transverse ligament, with the negative pad on the opposite side of the wrist. Apply only mild galvanic current for a period of 5 minutes,

being careful to watch the skin for irritation. While some patients' skin is more sensitive than others, it is typical to have some amount of redness following this treatment. After the treatment, apply a soothing lotion to the skin. This modality is normally used once or twice a week.

Like Dr. Cox, I also prescribe high potency bromelain and pyridoxal 5' phosphate orally, or use a B-Complex vitamin which contains high levels of pyridoxal 5' phosphate. Bromelain helps significantly in reducing the inflammation of tendinitis, which usually accompanies CTS, and of course, may also be used in the treatment of tendinitis which occurs elsewhere in the body."

Dr. Martinez - "Internally, one of the most effective things is to change them to a vegetarian diet, or a "natural hygiene" diet, similar to the Fit For Life approach. I use pyridoxal 5' phosphate (50 mg 2-3 times a day) and calcium-magnesium citrate.

I have also found about a 50% response to a 5-day therapeutic trial of undecylenic acid (10-undecenoic acid) as an anti-fungal agent, 200 mg three times a day, especially if their fingers are a little bit stiff in the morning, and their rings fit tightly. In the patients that respond, I suspect that there is a concurrent intestinal or systemic yeast infection present. Usually, these patients need to be treated for a period of 6-12 weeks to totally eliminate this Candida infection. I also may add digestive enzymes and an intestinal bulking agent. I also consider food allergies to be a strong component of CTS. Nutritionally, I usually find that there is the yeast syndrome, food sensitivities or a torpid liver.

If they respond partially to the undecylenic acid, but not totally, then I start thinking that hepatic-centered auto-toxicity may be present, in which case I use a silymarin (milk

thistle seed) extract to help clear out the liver, along with an herbal intestinal bulking formula, with psyllium and bentonite. If the patient presents with constipation or liver symptoms, then I am more likely to take this approach from the outset.”

David Cox, DC, a 1982 graduate of Los Angeles Chiropractic College, has practiced for fourteen years in both California and Idaho.

Robert M. Martinez, DC, ND, FACO graduated from Western States Chiropractic College in 1981 and John Bastyr College of Naturopathic Medicine in 1985. A board-certified Chiropractic Orthopedist, he is a member of the post-graduate faculty of Los Angeles College of Chiropractic and practices in Washington State.

Allen N. Tyler, MD, DC, ND, obtained his medical degree from La Universidad Libre Mexicano, his chiropractic degree from Canadian Memorial Chiropractic College and his naturopathic degree from Philadelphia College of Naturopathy. After years in private practice, he returned to academia in 1971, completing a three-year residency in Rehabilitation Medicine at the University of Washington Medical School. From 1974 through 1976, he served as Medical Director for the State of Washington Vocational Rehabilitation Program, before returning to clinical practice in British Columbia, where he practiced until his retirement in 1991.