

Natural Remedies for Scleroderma

Alan R. Gaby, MD

Abstract

Scleroderma is an autoimmune disease of the connective tissue characterized by fibrosis and thickening of various tissues. It can be limited to the skin or affect multiple organs, and its course ranges from slowly to rapidly progressive. Penicillamine, glucocorticoids, and other drugs are used to treat scleroderma, but none of these treatments has a high degree of efficacy. This article reviews several promising natural treatments for scleroderma, including para-aminobenzoic acid, vitamin E, vitamin D, evening primrose oil, estriol, N-acetylcysteine, bromelain, and an avocado/soybean extract. (*Altern Med Rev* 2006;11(3):188-195)

Introduction

Scleroderma (also called systemic sclerosis) is an autoimmune disease of the connective tissue. It is characterized by fibrosis in the skin and internal organs, resulting in thickening and hardening of the involved areas. There are two main subtypes of scleroderma: diffuse and limited. Diffuse scleroderma affects the skin and multiple organs and can be rapidly progressive and fatal. Limited scleroderma progresses more slowly. It often manifests as various components of a clinical pattern called the CREST syndrome (calcinosis cutis, Raynaud's phenomenon, esophageal involvement, sclerodactyly, and telangiectasia) (Figure 1). The disease may also be confined to the skin, without involvement of other organs, in which case it is called morphea or linear scleroderma. Medications used to treat scleroderma include penicillamine and other immunosuppressive agents, colchicine, and glucocorticoids. Table 1 illustrates the scleroderma subtypes.

Dietary Factors

Pathological changes in the gastrointestinal tract in patients with scleroderma can result in reduced colonic motility and prolonged transit time, which may lead to a state of chronic colonic pseudo-obstruction. In case reports, four patients with scleroderma developed severe abdominal pain after initiation of a high-fiber diet for the treatment of constipation; three of these patients required hospitalization.¹ The authors of this report suggested that, for patients with scleroderma, any increase in dietary fiber intake should be undertaken cautiously and introduced gradually.

Environmental Factors

Scleroderma can be induced by exposure to a number of different chemical agents, including organic solvents, plastics, certain drugs, silica powder, and silicone. In patients with chemical-induced scleroderma, eliminating the source of exposure (i.e., changing occupation, removing silicone breast implants) might favorably influence the course of the disease. A detoxification (depuration) program aimed at reducing the body burden of xenobiotic chemicals could conceivably slow or reverse the disease process, since such treatment has been beneficial in the treatment of other autoimmune diseases.²

PABA

Para-aminobenzoic acid (PABA) appears to have an antifibrotic action, suggested by its beneficial effect in patients with Peyronie's disease and Dupuytren's contracture. Zarafonietis reported in 1948

Alan R. Gaby, MD – Private practice 17 years, specializing in nutritional medicine; past-president, American Holistic Medical Association; contributing editor, *Alternative Medicine Review*; author, *Preventing and Reversing Osteoporosis* (Prima, 1994) and *The Doctor's Guide to Vitamin B6* (Rodale Press, 1984); co-author, *The Patient's Book of Natural Healing* (Prima, 1999); contributing medical editor, *The Townsend Letter for Doctors and Patients* since 1985.
Correspondence address: 301 Dorwood Drive, Carlisle, PA 17013

that PABA, usually administered as potassium para-aminobenzoate (KPAB), was an effective treatment for scleroderma. In patients who received this treatment, the skin gradually became softer and thinner, with consequent increased range of motion.³ In 1961, this same investigator presented data on 104 consecutive patients treated with 12 g KPAB daily. Ninety-seven patients (93.3%) showed moderate-to-considerable improvement of the involved skin. Some patients had a complete remission; in those cases, therapy was discontinued for up to 8.5 years without a recurrence. Most patients, however, showed some signs of residual activity and treatment was continued indefinitely.⁴

In 1988-1989, Zarafonitis et al presented a retrospective analysis of 390 scleroderma patients who had received adequate treatment with KPAB. "Adequate treatment" was defined in the analysis as 12 or 12.5 g per day for three months to 20.6 years (average, 4.2 years). The rate of decline in pulmonary function (vital capacity) was significantly less in these patients than in those who had been inadequately treated or never treated with KPAB.⁵ In addition, five-year (88.5% versus 69.8%) and 10-year (76.6% versus 56.6%) survival rates were significantly higher in adequately treated patients than in those who had never been treated.⁶

While other investigators have confirmed the effectiveness of PABA or KPAB,^{7,8} a double-blind trial found that administration of 12 g KPAB daily for 48 weeks had no effect on the skin lesions of scleroderma.⁹ However, the patients in that study had longstanding disease (mean duration, 8.67 years), which may have been too advanced to respond to KPAB.

Figure 1. CREST Syndrome

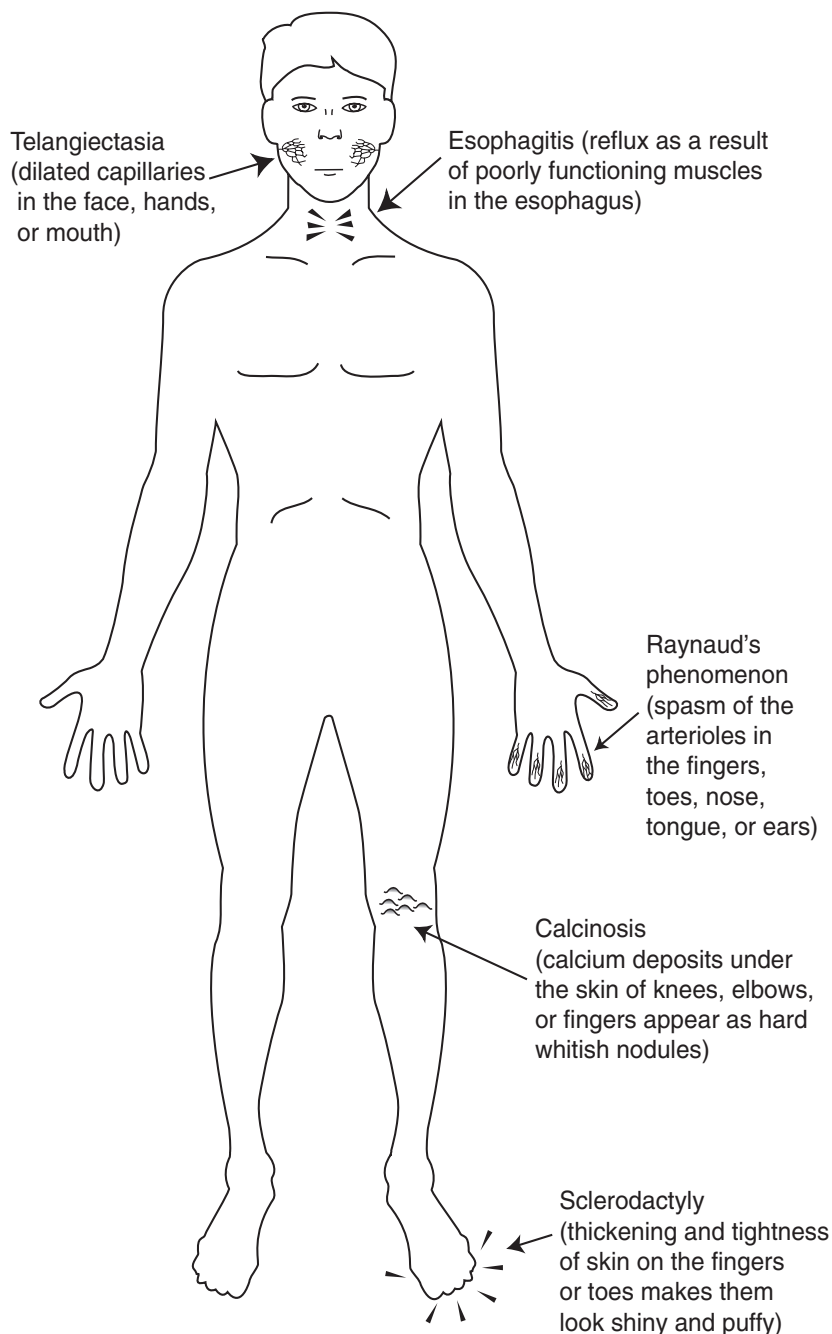


Table 1. Scleroderma Subtypes

Subtype	Characteristics
Diffuse	rapidly progressive
Limited	slowly progressive (may include calcinosis cutis, Raynaud's phenomenon, esophageal involvement, sclerodactyly, and telangiectasia)
Localized to the skin	morphea, linear scleroderma

Although KPAB was well tolerated by most scleroderma patients, this compound is not innocuous. Rare cases of hepatotoxicity and one death due to toxic hepatitis have been reported in patients receiving large doses of PABA or KPAB. Fever or rash may occur at doses greater than 12 g per day. Large doses may also cause hypoglycemia; treatment should therefore be interrupted during periods in which food intake is inadequate.

Vitamin E

Oxidative stress was significantly increased in patients with scleroderma compared with healthy controls, suggesting that free-radical-induced oxidative injury occurs in scleroderma.¹⁰ Antioxidants such as vitamin E might, therefore, be beneficial. Vitamin E is also believed to stabilize lysosomal membranes, potentially inhibiting events involved in the autoimmune process.¹¹ In addition, vitamin E may have an antifibrotic action, suggested by its beneficial effect in patients with Peyronie's disease and Dupuytren's contracture.

In case reports, vitamin E supplementation resulted in improvements in the skin of scleroderma patients, although non-dermatological aspects of the disease did not improve.¹²⁻¹⁵ Various components of scleroderma, including morphea, calcinosis cutis, and Raynaud's phenomenon, responded to vitamin E. The dose of vitamin E in these reports ranged from 200-1,200 IU per day. In some cases, vitamin E was also applied topically. One patient successfully

treated was a 45-year-old male with Raynaud's phenomenon, probable early scleroderma, and ulceration and gangrene of the fingertips. He received 800 IU oral vitamin E daily and applied the vitamin (50 IU per mL) to the ulcerated fingers twice daily. The ulcerations became less painful after two weeks and healed almost completely within one month.¹⁶

Vitamin D

A 1940 report described three patients with localized scleroderma who improved after treatment with vitamin D2 at a dose of 10,000-12,500 IU per day for 1-3 months.¹⁷ That report did not attract much interest, possibly because of the potential for high-dose vitamin D2 to cause toxic effects. More recently, several studies have demonstrated the effectiveness of orally administered 1,25-dihydroxycholecalciferol (calcitriol), the biologically active form of vitamin D, as a treatment for scleroderma. Calcitriol has several actions that might be expected to slow or reverse the disease process, including immunoregulatory effects and inhibition of fibroblast growth and collagen synthesis.

A 35-year-old woman with a two-year history of localized scleroderma was given calcitriol for six months. The initial dose was 0.25 mcg per day for one week, increased by 0.25 mcg per day each week until a dosage of 1.25 mcg daily was reached in the fifth week. Thereafter, 0.5 mcg per day was given for four months. After six months of treatment, the skin lesions had almost completely resolved.¹⁸

Three patients with generalized morphea received 0.5-0.75 mcg calcitriol daily. After 3-7 months of treatment, joint mobility improved and skin extensibility increased. No adverse effects were seen. The improvement persisted after discontinuation of therapy during a 1- to 2-year follow-up period.¹⁹

Seven children (ages 3-13 years) with linear scleroderma received 0.25 mcg calcitriol daily for one week; this was increased every week to a maximum of 0.5-1.25 mcg per day, depending on body surface area and response to treatment. Dietary calcium intake was restricted to 600 mg daily. Five of seven patients showed good-to-excellent improvement of their lesions. One patient had a partial relapse after 19 months, but responded well to a second course of therapy. No significant side effects were seen. The authors suggested that calcitriol be tried for at least three months in children with linear scleroderma before introducing more aggressive therapy. If improvement is seen, this treatment may be continued for 6-9 months.²⁰

Eleven scleroderma patients were treated with 0.25 mcg calcitriol daily during the first week; calcitriol was increased by 0.25 mcg daily each week until urinary or serum calcium levels became elevated. The mean final dose was 1.75 mcg per day and the maximum dose was 2.5 mcg per day. After treatment periods ranging from six months to three years, significant improvements in skin thickness and extensibility were observed. No serious side effects were seen except for transient hypercalciuria (always below 350 mg per day), which responded to a temporary reduction in the dosage.²¹

Twenty patients with morphea were randomly assigned to receive, in double-blind fashion, calcitriol (0.75 mcg per day for six months, followed by 1.25 mcg per day for three months) or placebo for nine months. The severity of the skin condition decreased 19 percent in the calcitriol group and 29 percent in the placebo group (difference not significant).²²

Thus, most but not all clinical trials have shown that calcitriol treatment improves the skin manifestations of scleroderma. However, in addition to being expensive, calcitriol can cause hypercalcemia, hypercalciuria, and other side effects requiring frequent monitoring with laboratory tests. While calcitriol treatment would be worthwhile in selected

cases, vitamin D3 (cholecalciferol) might be a viable alternative for many patients, even though it has not been subjected to clinical trials. In addition to being inexpensive and less toxic than vitamin D2, vitamin D3 is 3.4-9.4 times as potent in humans as vitamin D2.²³ The vitamin D2 dosage range of 10,000-12,500 IU per day reported to be effective against scleroderma would correspond to approximately 1,100-3,700 IU of vitamin D3 daily. Studies in healthy humans suggest that 4,000 IU vitamin D3 per day for 2-5 months is a safe level of intake.²⁴ Patients receiving high-dose vitamin D3 for long periods of time and those being treated with calcitriol should be monitored for signs of toxicity.

Evening Primrose Oil

Evening primrose oil (EPO) contains a high concentration of gamma-linolenic acid (GLA), which is a precursor to prostaglandin E1 (PGE1). In patients with Raynaud's phenomenon associated with scleroderma, intravenously administered PGE1 increased capillary blood flow and appeared to promote ulcer healing.²⁵ Because PGE1 is unstable and must be administered intravenously, an effective orally active alternative would be desirable.

Four women with scleroderma of 5-13 years' duration received 1 g EPO three times daily for one year. Pain in the hands and feet was reduced, ulcers healed, and skin texture and telangiectasia improved.²⁶

Twenty-one patients with Raynaud's phenomenon (with or without scleroderma) received, in double-blind fashion (randomization not specified), 6 g EPO per day, providing 540 mg GLA daily, or placebo for eight weeks. The EPO group experienced fewer attacks than the placebo group, and the difference reached statistical significance at six and eight weeks ($p < 0.03$). Patients with Raynaud's phenomenon associated with scleroderma appeared to be more likely to improve with EPO, compared with patients with Raynaud's disease and no evidence of a connective tissue disorder.²⁷

In a double-blind study, 25 patients with scleroderma received a placebo or a preparation containing EPO and fish oil for six months. The number and duration of attacks of Raynaud's phenomenon decreased in both groups, but there was no significant

difference between groups.²⁸ The authors concluded that EPO/fish oil did not improve vascular symptoms in patients with scleroderma; however, the conclusion is open to question for two reasons. First, the “placebo” in the study was sunflower oil, a source of linoleic acid, which can be converted *in vivo* to GLA. It is possible, therefore, that both EPO/fish oil and the placebo were beneficial. Second, the EPO/fish oil preparation also provided 30 mg lithium per day. Because lithium appears to interfere with essential fatty acid metabolism,²⁹ it may have blocked a beneficial effect of EPO/fish oil.

Although more definitive studies need to be conducted, the available evidence suggests that EPO may be beneficial in the treatment of scleroderma and the associated Raynaud’s phenomenon.

Estriol

Several lines of evidence led a group of investigators to consider estriol as a possible treatment for scleroderma: the condition affects women primarily, it sometimes improves during pregnancy, urinary estriol levels rise during late pregnancy, and estriol has a softening effect on the uterine cervix. Two women (ages 48 and 59 years, respectively) with scleroderma were treated with estriol for 10 months. The first patient received 10 mg per week subcutaneously; the second received 2 mg per day orally, followed by 10–20 mg per week subcutaneously, after the oral dose was discontinued because of urticaria. Skin softening was noted on all involved areas in both patients, and was accompanied by increased mobility of large and medium-sized joints, a lessening of cyanosis on fingers and extremities, and marked histologic improvement of affected skin.³⁰

Until more is known, it would seem reasonable to reserve estriol therapy for postmenopausal women or for premenopausal women with evidence of estrogen deficiency.

N-Acetylcysteine

Twenty patients with Raynaud’s phenomenon secondary to scleroderma received a five-day continuous infusion of N-acetylcysteine during the winter, starting with a loading dose of 150 mg per kg body weight given over two hours, followed by 15 mg per kg body weight per hour for the remainder of

the treatment period. During the ensuing eight weeks, the frequency and severity of attacks decreased significantly compared with baseline. Of the 17 patients with digital ischemic ulcers, eight experienced complete healing. Side effects were considered by the authors of the study to be minor and reversible.³¹

S-Adenosylmethionine

Fifteen patients with scleroderma received 600 mg S-adenosylmethionine per day intravenously for two months, followed by 400 mg three times per day orally. After four months, 10 patients showed a significant improvement in skin induration. In three patients who underwent skin biopsy, a significant reduction in the thickness of the dermal layer was seen. No improvement was seen in esophageal disease or in Raynaud’s phenomenon.³²

Bromelain

A 32-year-old woman with early biopsy-proven scleroderma was treated with enteric-coated bromelain (Ananase), first 160 mg per day and later 80 mg per day. After three months, she was able to close her hand 85 percent, compared with 50 percent before treatment. Swallowing function, which had been impaired for several years, also improved. These improvements were maintained during a one-year total treatment period.³³

The product used in this study is no longer commercially available. Non-enteric-coated bromelain would presumably be partially inactivated by gastric enzymes after ingestion. While clinical experience suggests that currently available bromelain products do have biological activity, dosage comparisons with Ananase are difficult.

Avocado/Soybean Extract

One practitioner has reported good results using an unsaponifiable fraction of avocado/soybean (ASU [Piascledine 300; Pharmascience Laboratories, Courbevoie, France]) in more than 100 patients with extensive plaque-like morphea or linear scleroderma. If treatment was initiated at an early stage of linear scleroderma, then contractures, atrophy, and deformities of the extremities were avoided. The usual dose of ASU was 300 mg daily for six months, but some patients were treated for 1–2 years. In severe cases,

Table 2. Alternative Treatments for Scleroderma

TREATMENT	DOSAGE	RATIONALE
Fiber	Use with caution	Decreased colonic motility
Para-aminobenzoic Acid (PABA)	12 g/day KPABA (potassium-PABA)	Anti-fibrotic
Vitamin E	200-1,200 IU/day orally; topical application	Antioxidant; anti-fibrotic
Vitamin D	0.25-1.25 mcg/day calcitriol OR 1,000-4,000 IU/day D3 (not studied)	Immunoregulatory; inhibition of fibroblast growth and collagen synthesis
GLA (sources: black currant, borage, or evening primrose oil)	540 mg/day GLA (evening primrose oil used in the studies)	Converts to prostaglandin E1 to increase capillary flow and decrease inflammation; especially for patients with concomitant Raynaud's phenomenon
Estriol	2 mg/day orally OR 10-20 mg/week subcutaneously	Mechanism unknown
N-acetylcysteine	IV infusion of 15-150 mg/kg/hour for five days	Mechanism unknown
S-adenosylmethionine (SAME)	IV infusion of 600 mg/day followed by 400 mg three times daily	Mechanism unknown
Bromelain	80-160 mg/day enterically coated	Mechanism unknown
Avocado/Soybean Extract (unsaponifiable)	300-600 mg/day	Mechanism unknown
Zinc/Copper	15-60 mg/day zinc; 1-4 mg/day copper	Correct a deficiency

600 mg per day was used. No side effects were observed.³⁴

The interpretation of this report is complicated by the fact that the patients were given procaine penicillin before starting treatment with ASU. According to some researchers, an infectious agent may play a role in the causation of scleroderma,³⁵ and the disease has been reported to improve after treatment with penicillin alone.³⁶

Zinc/Copper

Markedly reduced zinc levels were found in erythrocytes, platelets, and granulocytes of patients with scleroderma.³⁷ While the clinical significance of these findings is not clear, loss of taste function (suggestive of zinc deficiency) has been reported in scleroderma patients during treatment with penicillamine.³⁸ The interaction between penicillamine and

zinc is complex,³⁹ the drug increases intestinal absorption, urinary excretion, and serum levels of zinc, but might also promote zinc deficiency. Large doses of zinc may increase penicillamine toxicity, possibly because both compounds deplete copper. Long-term zinc supplementation should normally be accompanied by a copper supplement (1-4 mg per day, depending on the zinc dose), in order to prevent zinc-induced copper deficiency.⁴⁰ If zinc and penicillamine are used together, then the dose of copper should perhaps be somewhat larger.

Combining Treatments

All of the treatments described above have been studied individually. Because some of them probably have different mechanisms of action, combination therapy might be more effective than any single treatment alone. In addition, as is often observed clinically with nutritional therapy, nutrients used in combination may be effective at lower doses than when used individually. That possibility is worth noting with respect to KPAB and vitamin D, the adverse effects of which are dose-related. Nutrient dosages should be chosen with consideration of the severity and rate of progression of the illness, and should be adjusted according to clinical response and tolerance.

Table 2 summarizes alternative treatment options for scleroderma.

Conclusion

Although a cure remains elusive, the treatments described in this article have the potential to improve outcomes for patients suffering from scleroderma. In most instances, the improvements were limited to the cutaneous manifestations of the disease. However, treatment with PABA appeared to have a favorable influence on the internal pathology as well, and also reduced long-term morbidity and mortality. The improvement in swallowing function that occurred in a patient treated with bromelain suggests that this treatment may also have a beneficial effect on internal organ involvement. Because of their relative safety and low cost, further investigation is warranted for the natural remedies discussed in this review.

References

1. Gough A, Sheeran T, Bacon P, Emery P. Dietary advice in systemic sclerosis: the dangers of a high fibre diet. *Ann Rheum Dis* 1998;57:641-642.
2. Crinnion WJ. Results of a decade of naturopathic treatment for environmental illnesses: a review of clinical records. *J Naturopathic Med* 1997;7:21-27.
3. Zarafonitis CJ. Para-aminobenzoic acid therapy in scleroderma and lymphoblastoma cutis. *J Lab Clin Med* 1948;33:1462-1463.
4. Zarafonitis CJ. The treatment of scleroderma: results of potassium para-aminobenzoate therapy in 104 cases. In: Mills LC, Moyer JH, eds. *Inflammation and Diseases of Connective Tissue*. W.B. Saunders Co.; 1961:688-696.
5. Zarafonitis CJ, Dabich L, Devol EB, et al. Retrospective studies in scleroderma: pulmonary findings and effect of potassium p-aminobenzoate on vital capacity. *Respiration* 1989;56:22-33.
6. Zarafonitis CJ, Dabich L, Negri D, et al. Retrospective studies in scleroderma: effect of potassium para-aminobenzoate on survival. *J Clin Epidemiol* 1988;41:193-205.
7. Grace WJ, Kennedy RJ, Formato A. Therapy of scleroderma and dermatomyositis. *N Y State J Med* 1963;63:140-144.
8. Bushnell WJ, Galens GJ, Bartholomew LE, et al. The treatment of progressive systemic sclerosis: a comparison of para-aminobenzoate and placebo in a double blind study. *Arthritis Rheum* 1966;9:495-496.
9. Clegg DO, Reading JC, Mayes MD, et al. Comparison of aminobenzoate potassium and placebo in the treatment of scleroderma. *J Rheumatol* 1994;21:105-110.
10. Stein CM, Tanner SB, Awad JA, et al. Evidence of free radical-mediated injury (isoprostane overproduction) in scleroderma. *Arthritis Rheum* 1996;39:1146-1150.
11. Ayres S Jr, Mihan R. Is vitamin E involved in the autoimmune mechanism? *Cutis* 1978;21:321-325.
12. Ayres S Jr, Mihan R. Vitamin E (tocopherol) – a reappraisal of its value in dermatoses of mesodermal tissues. *Cutis* 1971;7:35-45.
13. Ayres S Jr, Mihan R. Vitamin E and dermatology. *Cutis* 1975;16:1017-1021.
14. Kraus Z. Fibrosis of the lungs in scleroderma. *Nutr Abs Rev* 1950;20:452.
15. Ayres S Jr, Mihan R, Levan NE, et al. Raynaud's phenomenon, scleroderma and calcinosis cutis: response to vitamin E. *Cutis* 1973;11:54-62.
16. Ayres S Jr, Mihan R, Levan NE. Raynaud's phenomenon and possibly early scleroderma – response to vitamin E. *Arch Dermatol* 1971;104:570-571.

17. Maynard MT. Vitamin therapy in dermatology. With particular reference to vitamin D in the treatment of acne and of diseases due to altered usage of calcium. *Arch Derm Syphilol* 1940;41:842-857.
18. Humbert PG, Dupond JL, Rochefort A, et al. Localized scleroderma – response to 1,25-dihydroxyvitamin D3. *Clin Exp Dermatol* 1990;15:396-398.
19. Hulshof MM, Pavel S, Breedveld FC, et al. Oral calcitriol as a new therapeutic modality for generalized morphea. *Arch Dermatol* 1994;130:1290-1293.
20. Elst EF, Van Suijlekom-Smit LW, Oranje AP. Treatment of linear scleroderma with oral 1,25-dihydroxyvitamin D3 (calcitriol) in seven children. *Pediatr Dermatol* 1999;16:53-58.
21. Humbert P, Dupond JL, Agache P, et al. Treatment of scleroderma with oral 1,25-dihydroxyvitamin D3: evaluation of skin involvement using non-invasive techniques. Results of an open prospective trial. *Acta Derm Venereol* 1993;73:449-451.
22. Hulshof MM, Bouwes Bavinck JN, Bergman W, et al. Double-blind, placebo-controlled study of oral calcitriol for the treatment of localized and systemic scleroderma. *J Am Acad Dermatol* 2000;43:1017-1023.
23. Armas LA, Hollis BW, Heaney RP. Vitamin D2 is much less effective than vitamin D3 in humans. *J Clin Endocrinol Metab* 2004;89:5387-5391.
24. Vieth R, Chan PC, MacFarlane GD. Efficacy and safety of vitamin D3 intake exceeding the lowest observed adverse effect level. *Am J Clin Nutr* 2001;73:288-294.
25. Martin MF, Tooke JE. Effects of prostaglandin E1 on microvascular haemodynamics in progressive systemic sclerosis. *Br Med J (Clin Res Ed)* 1982;285:1688-1690.
26. Strong AM, Campbell A, Thomson J. The effect of oral linoleic acid and gamma-linolenic acid (Efamol [G]). *Br J Clin Pract* 1985;39:444-445.
27. Belch JJ, Shaw B, O'Dowd A, et al. Evening primrose oil (Efamol) in the treatment of Raynaud's phenomenon: a double blind study. *Thromb Haemost* 1985;54:490-494.
28. Stainforth JM, Layton AM, Goodfield MJ. Clinical aspects of the use of gamma linolenic acid in systemic sclerosis. *Acta Derm Venereol* 1996;76:144-146.
29. Lieb J. Linoleic acid in the treatment of lithium toxicity and familial tremor. *Prostaglandins Med* 1980;4:275-279.
30. Katayama H, Ohsawa K, Yaoita H. Improvement of progressive systemic sclerosis (PSS) with estriol treatment. *Acta Derm Venereol* 1984;64:168-171.
31. Sambo P, Amico D, Giacomelli R, et al. Intravenous N-acetylcysteine for treatment of Raynaud's phenomenon secondary to systemic sclerosis: a pilot study. *J Rheumatol* 2001;28:2257-2262.
32. Oriente P, Scarpa R, Biondi C, et al. Progressive systemic sclerosis and S-adenosylmethionine. *Clin Rheumatol* 1985;4:360-361.
33. Pierce HE Jr. Pineapple proteases in the treatment of scleroderma. A case report. *J Natl Med Assoc* 1964;56:272-273.
34. Jablonska S. Avocado/soybean unsaponifiables in the treatment of scleroderma: comment on the article by Maheu et al. *Arthritis Rheum* 1998;41:1705.
35. Cantwell AR Jr, Craggs E, Wilson JW, Swatek F. Acid-fast bacteria as a possible cause of scleroderma. *Dermatologica* 1968;136:141-150.
36. Mohrenschlager M, Jung C, Ring J, Abeck D. Effect of penicillin G on corium thickness in linear morphea of childhood: an analysis using ultrasound technique. *Pediatr Dermatol* 1999;16:314-316.
37. Svenson KL, Hallgren R, Johansson E, Lindh U. Reduced zinc in peripheral blood cells from patients with inflammatory connective tissue diseases. *Inflammation* 1985;9:189-199.
38. Keiser HR, Henkin RI, Bartter FC, Sjoerdsma A. Loss of taste during therapy with penicillamine. *JAMA* 1968;203:381-383.
39. Ambanelli U, Ferraccioli GF. D-Penicillamine and zinc. *Arthritis Rheum* 1978;21:396.
40. Fosmire GJ. Zinc toxicity. *Am J Clin Nutr* 1990;51:225-227.